

Anatomy Pathways™ for VH Dissector™

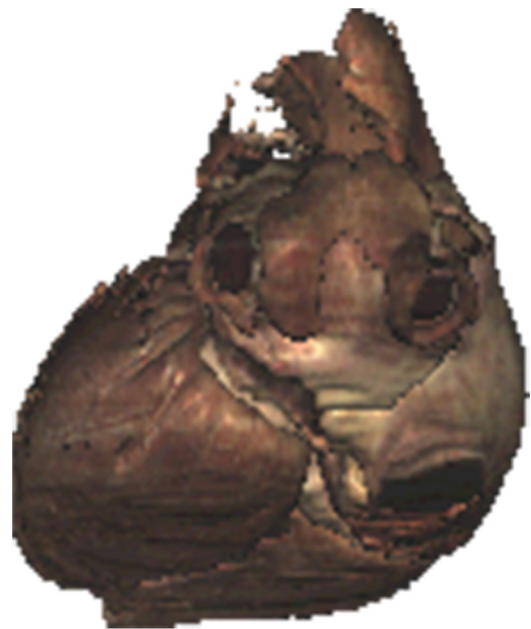Cardiovascular System – Heart Anatomy




Identify the following structures in the images below.

(Some structures may be visible in more than one image.)


epicardium • myocardium • endocardium • ligamentum arteriosum
right atrium • right ventricle • left ventricle • left atrium



What is the *pericardium*?



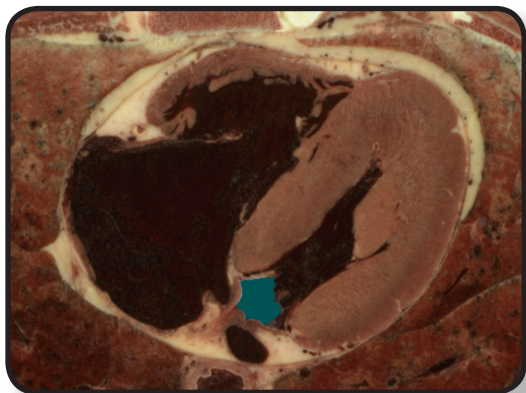
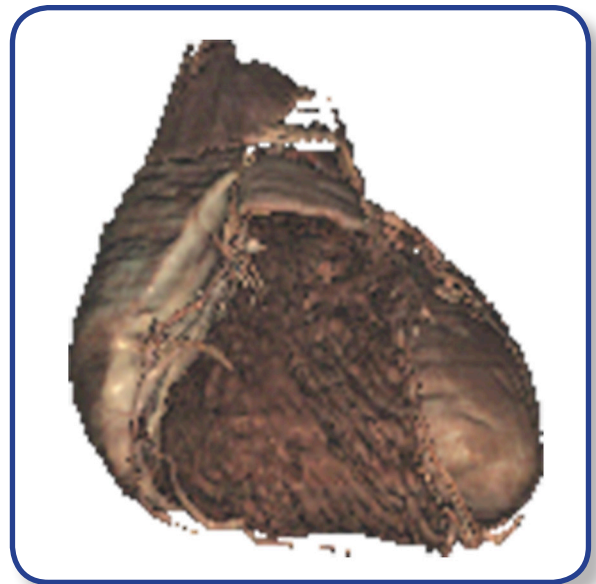
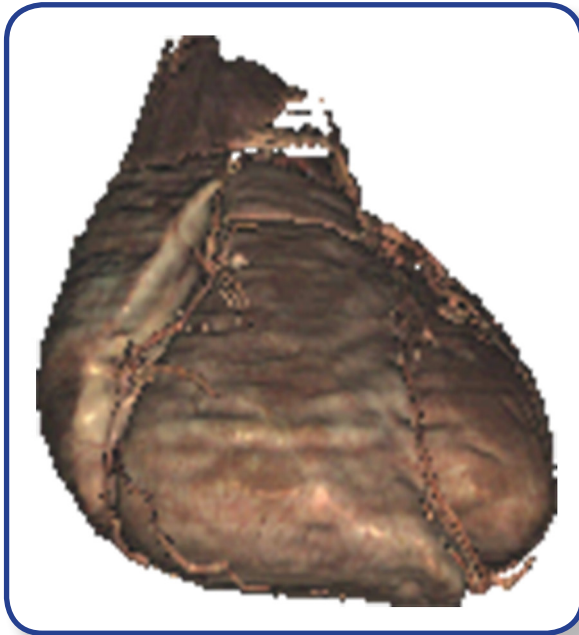
What is the *mediastinum*?



Cardiovascular System – Heart Anatomy

Identify the following structures in the images below.
(Some structures may be visible in more than one image.)

coronary artery • interventricular artery • cardiac veins • marginal vein
greater cardiac vein • trabeculae carneae • papillary muscles
pulmonary valve • interventricular septum



What are the *chordae tendineae*?

