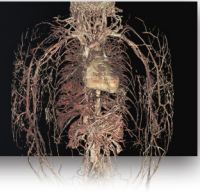

Anatomy Pathways™ for VH Dissector™

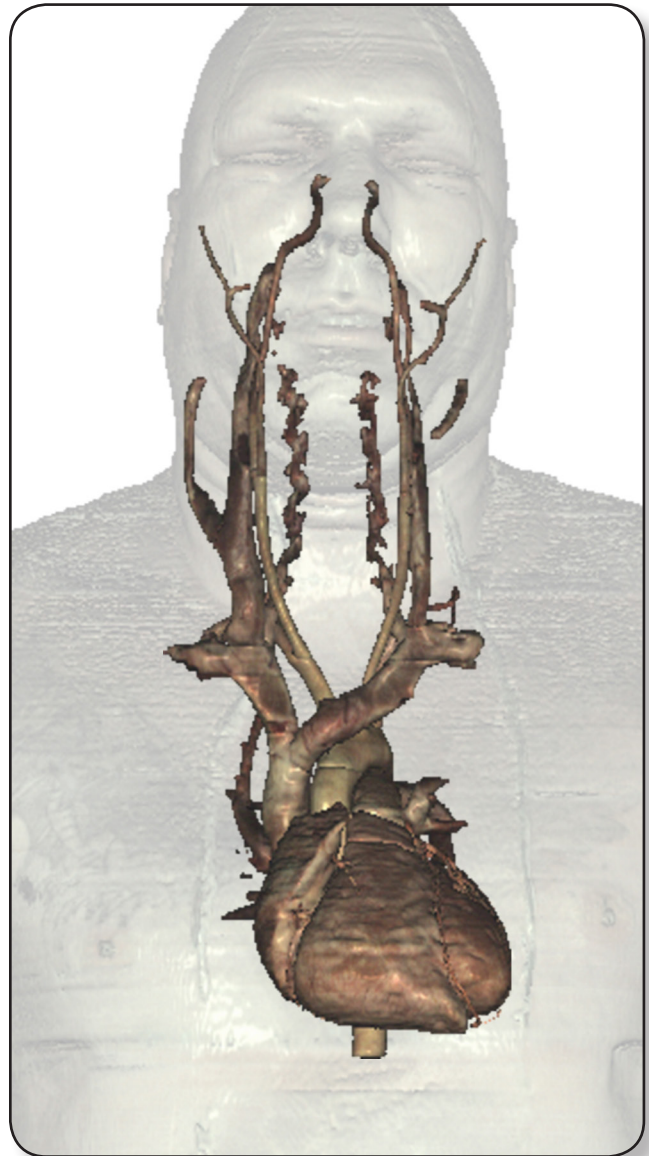
Upper Body Vasculature



Identify the following structures in the images below.

(Some structures may be visible in more than one image.)

pulmonary arteries • superior pulmonary veins • inferior pulmonary veins
aortic arch • thoracic aorta • brachiocephalic trunk • common carotid arteries
subclavian arteries • internal carotid arteries • external carotid arteries
superior vena cava • brachiocephalic veins • subclavian veins • vertebral veins
internal jugular veins • external jugular veins



Upper Body Vasculature

Identify the following structures in the images below.
(Some structures may be visible in more than one image.)

superior vena cava • brachiocephalic veins • subclavian veins • axillary veins
brachial veins • radial veins • ulnar veins • aortic arch • thoracic aorta
brachiocephalic trunk • subclavian arteries • axillary arteries • brachial arteries
radial arteries • ulnar arteries

