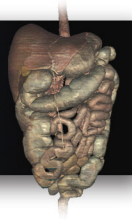

# Anatomy Pathways™ for VH Dissector™

## Digestive System



Identify the following structures in the images below.  
(Some structures may be visible in more than one image.)

esophagus • stomach (cardia, fundus, body, pylorus) • small intestine • pyloric sphincter  
duodenum • jejunum • ileum • large intestine • cecum • ascending colon  
transverse colon • descending colon • sigmoid colon • rectum internal anal sphincter  
external anal sphincter • appendix

Describe the *hard* and *soft* palates.

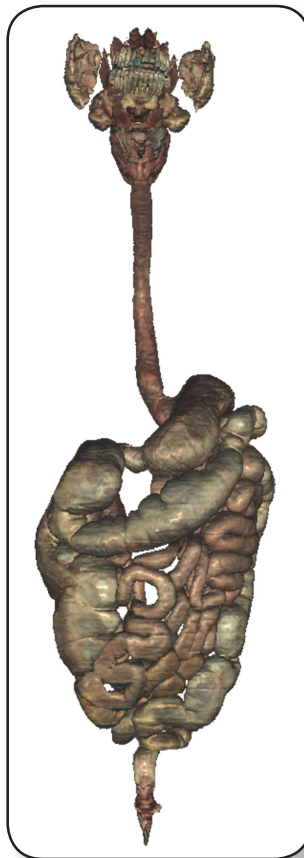
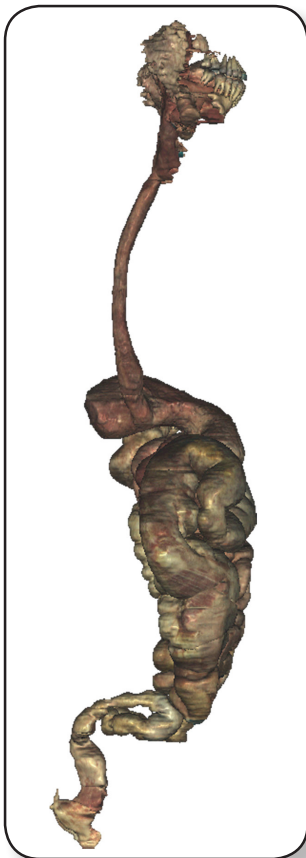---

---

What is the *uvula*?

---

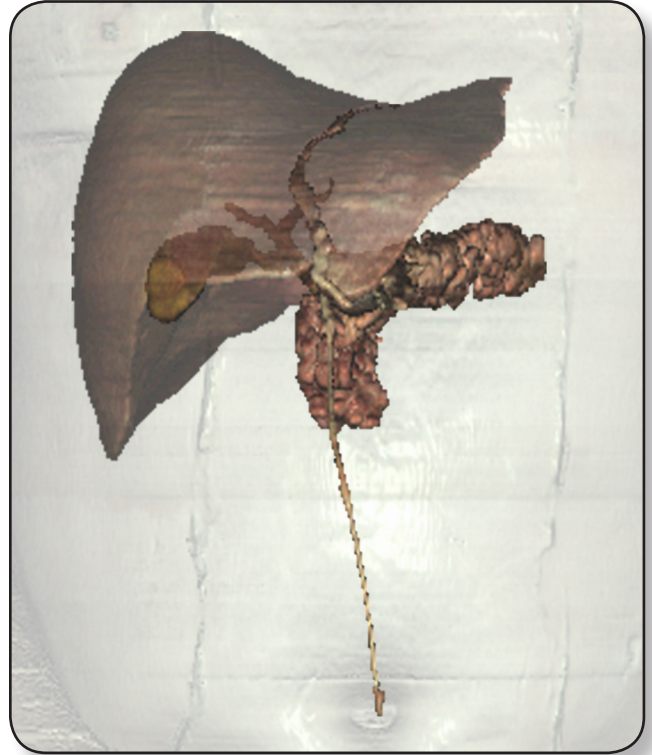
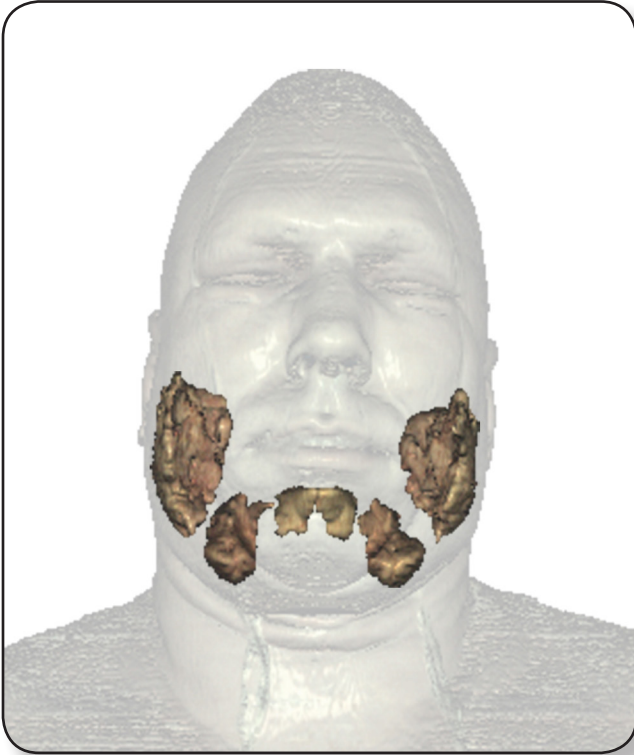
---



# Digestive System

Identify the following structures in the images below.  
(Some structures may be visible in more than one image.)

parotid glands • submandibular glands • sublingual glands • liver • gallbladder  
falciform ligament • round ligament • common hepatic duct • cystic duct • bile duct  
pancreas • pancreatic duct



What is the function of the *gastro-esophageal sphincter*?

---

---

What is the function of the *pyloric sphincter*?

---

---

What is meant by *retroperitoneal*?

---

---