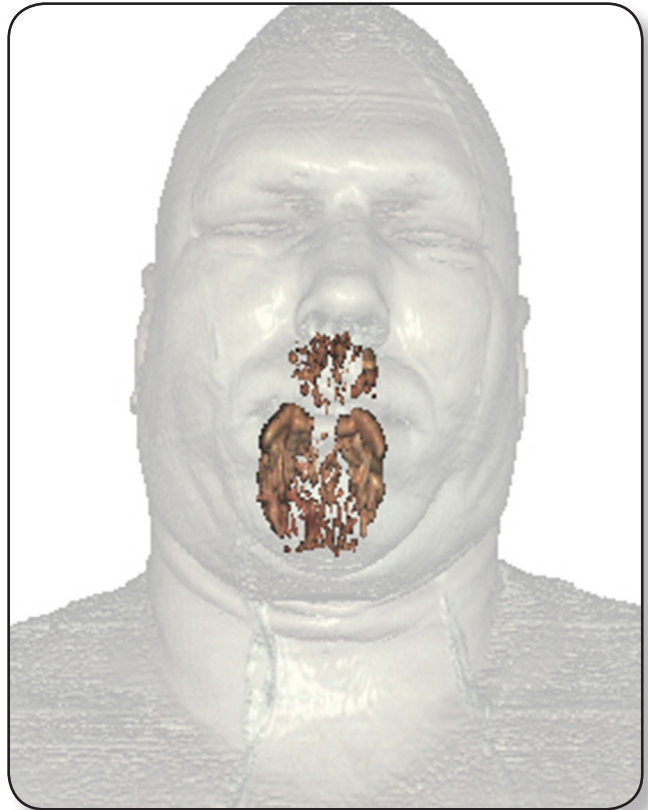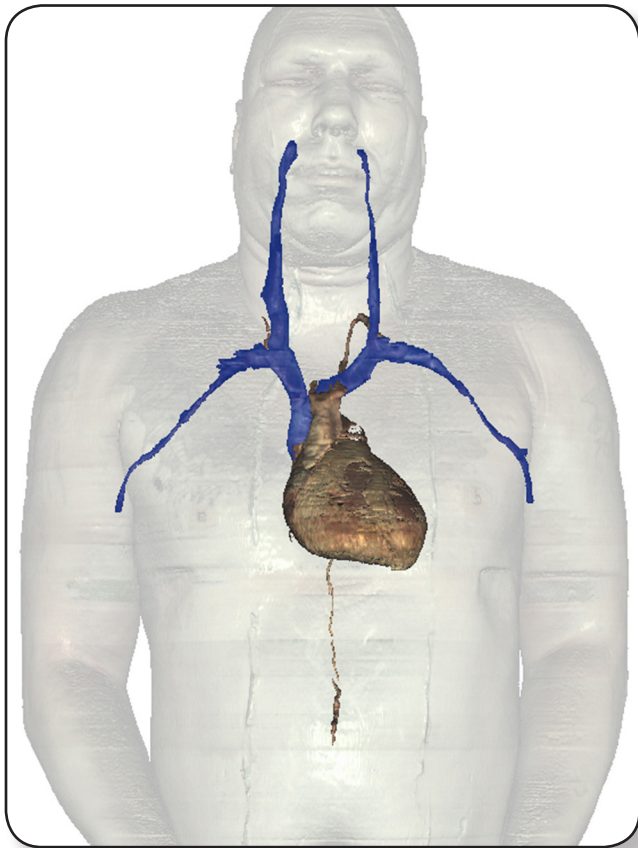


Anatomy Pathways™ for VH Dissector™

Lymphatic System

Identify the following structures in the images below.
(Some structures may be visible in more than one image.)

thoracic duct • right thoracic duct • thymus • pharyngeal tonsils
palatine tonsils • lingual tonsils • tonsillectomy • cisterna chyli

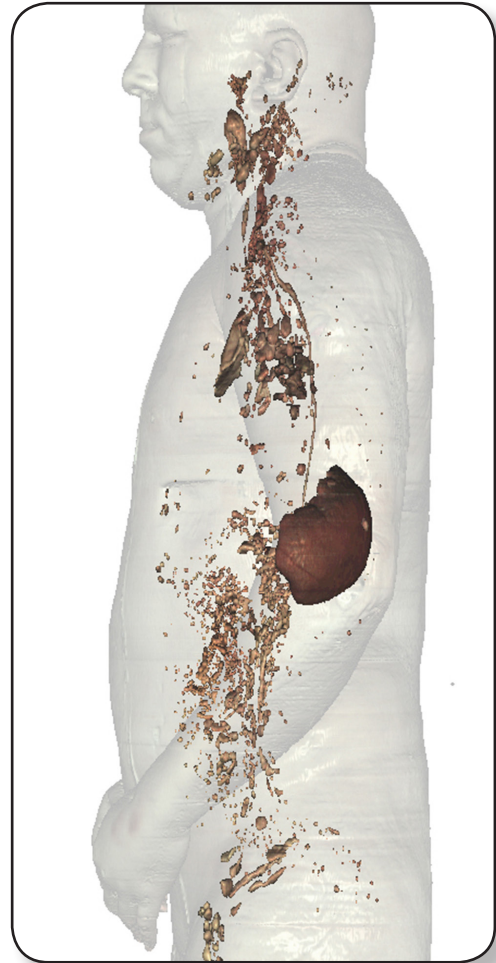
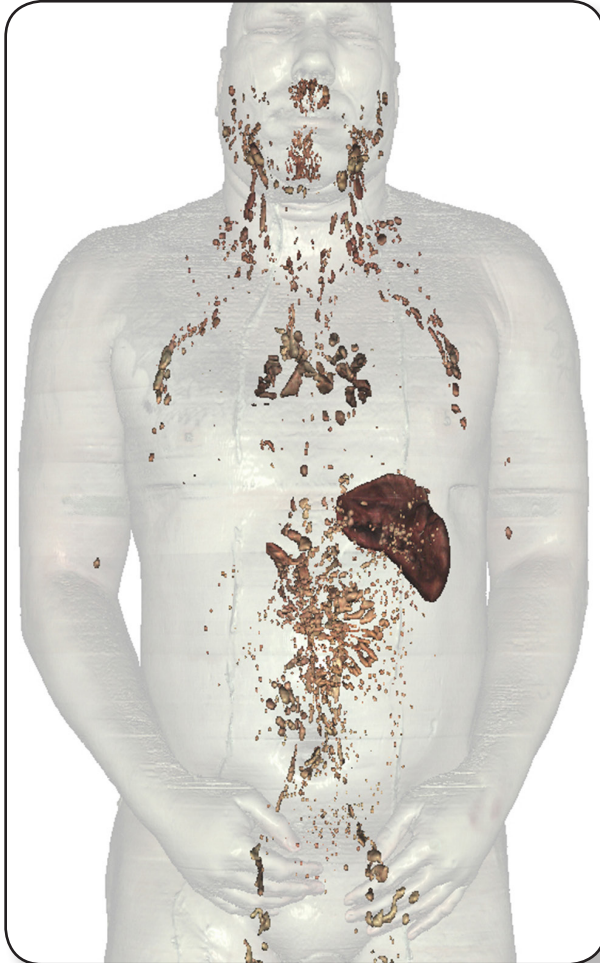
Describe the *cisterna chyli*.

Lymphatic System

Identify the following structures in the images below.
(Some structures may be visible in more than one image.)

lymph nodes • primary lymphatic organs • secondary lymphatic organs • spleen
lymphatic nodules • pharyngeal tonsils • palatine tonsils • lingual tonsils



How is *red bone marrow* related to the *lymphatic system*?

What are *Peyer's patches*?
