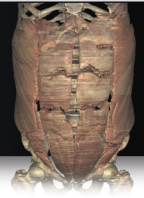

# Anatomy Pathways™ for VH Dissector™

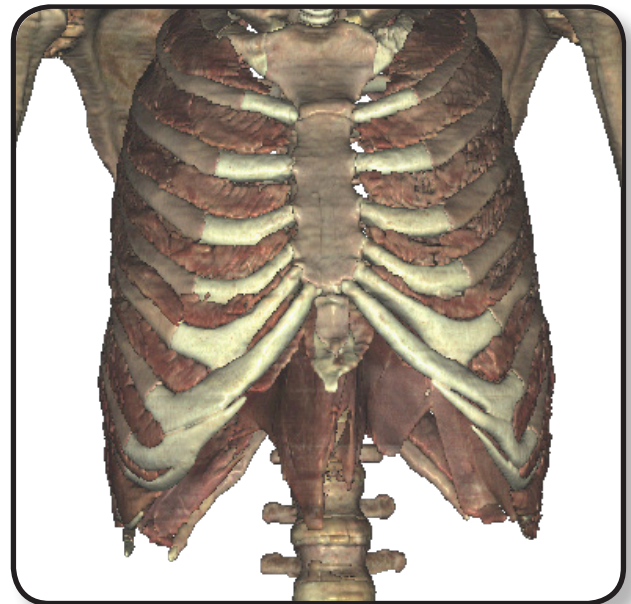
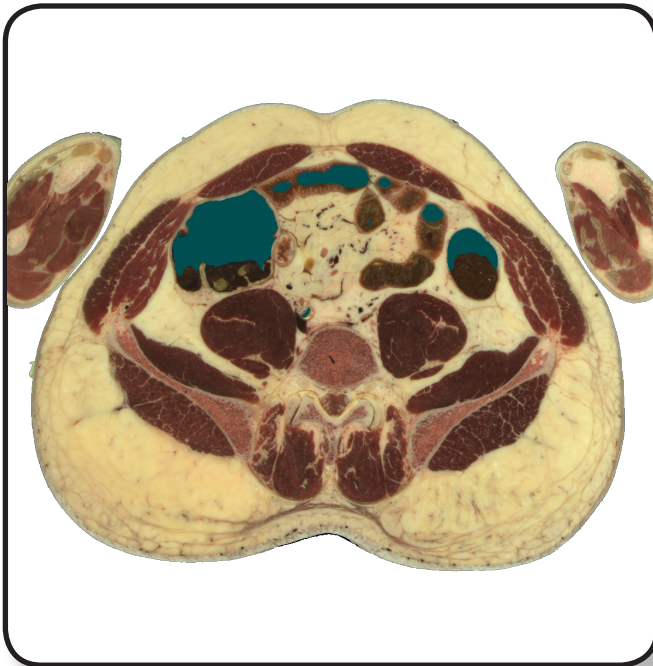## Muscular System – Abdominal & Breathing Muscles



Identify the following structures in the images below.

(Some structures may be visible in more than one image.)

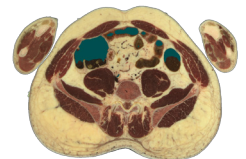
transversus abdominis • internal oblique • external oblique  
rectus abdominis • external intercostals • internal intercostals • diaphragm



What is the function of the *rectus sheaths*?

---

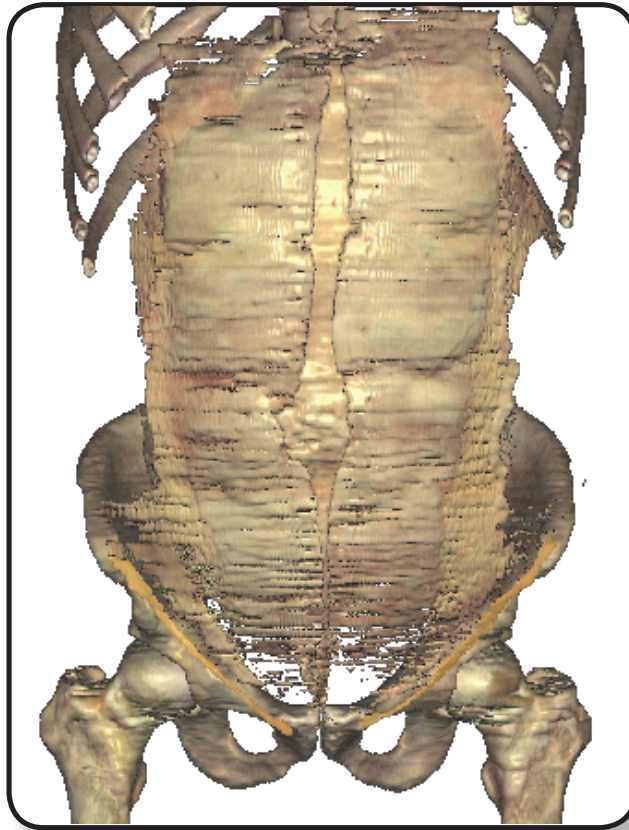
---



## Muscular System – Abdominal & Breathing Muscles

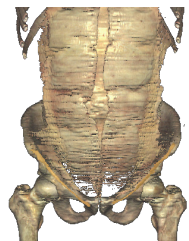
Identify the following structures in the images below.  
(Some structures may be visible in more than one image.)

external oblique aponeurosis • linea alba • internal oblique aponeurosis • inguinal canal



The *transversus abdominis aponeurosis* is not visible in the image above because it is located posterior to what other aponeuroses?

1. \_\_\_\_\_
2. \_\_\_\_\_
3. \_\_\_\_\_



What is the *inguinal canal* and what is its function?

\_\_\_\_\_

\_\_\_\_\_

\_\_\_\_\_

