

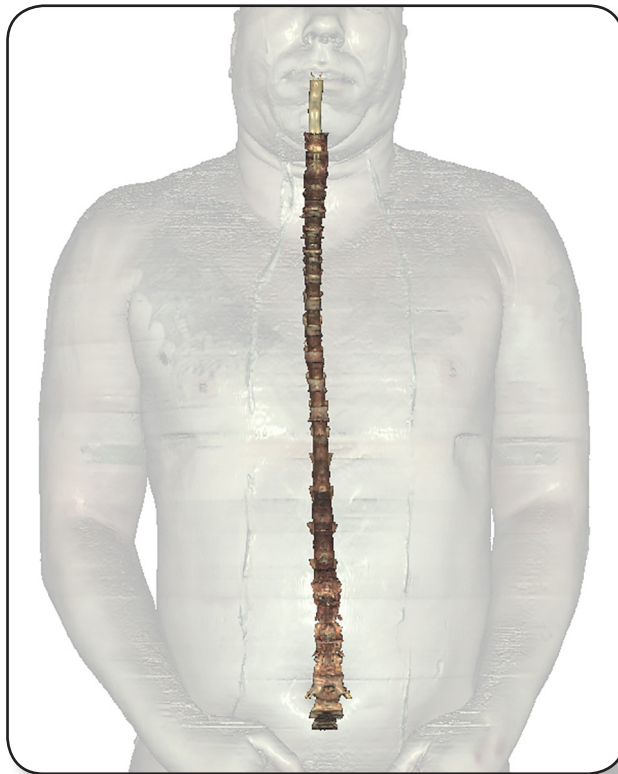# Anatomy Pathways™ for VH Dissector™

## Spinal Cord & Spinal Nerves



Identify the following structures in the images below.  
(Some structures may be visible in more than one image.)

dura mater • epidural space • cerebrospinal fluid space  
conus medullaris • cauda equina • filum terminale



What are the *meninges* and what is their function?

---

---

Where is the *arachnoid mater* located?

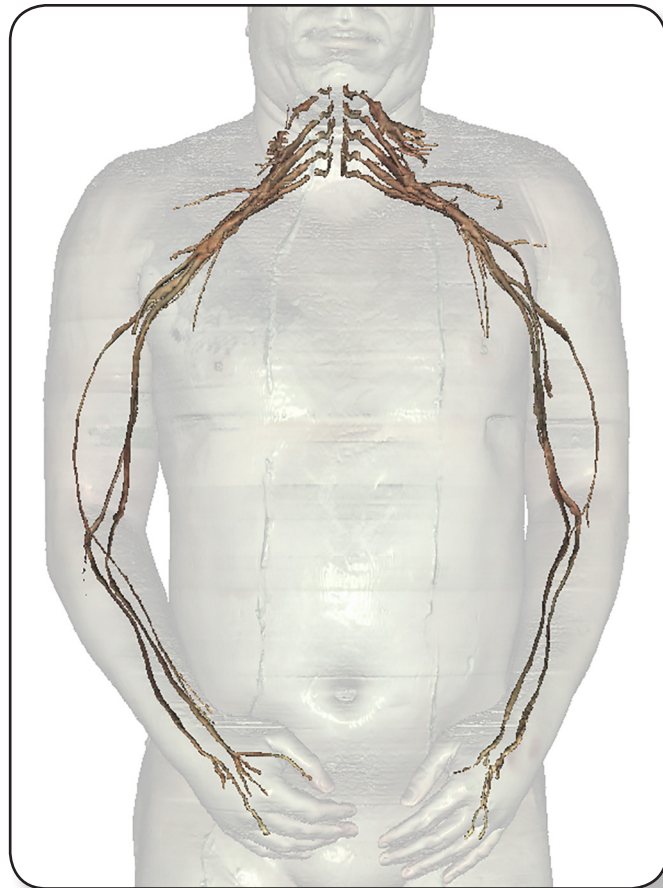
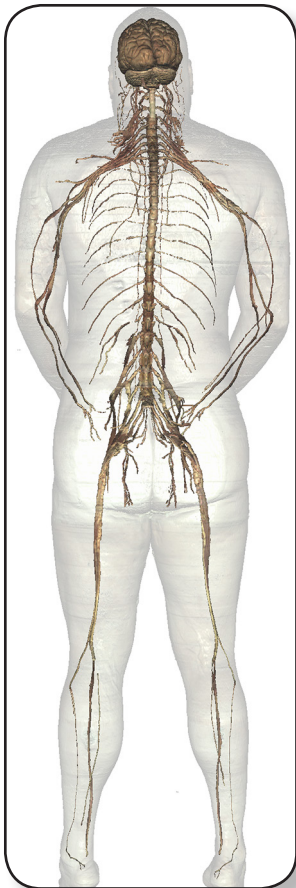---

---

# Spinal Cord & Spinal Nerves

Identify the following structures in the images below.  
(Some structures may be visible in more than one image.)

brachial plexus • sacral plexus • coccygeal plexus • sciatic nerve  
musculocutaneous nerve • median nerve • radial nerve • ulnar nerve • axillary nerve  
obturator nerve • tibial nerve • common fibular nerve • pudendal nerve



Where is the *subarachnoid space* and what is its significance to a lumbar puncture procedure?

---

---

Where is the *subdural space* and what is contained within it?

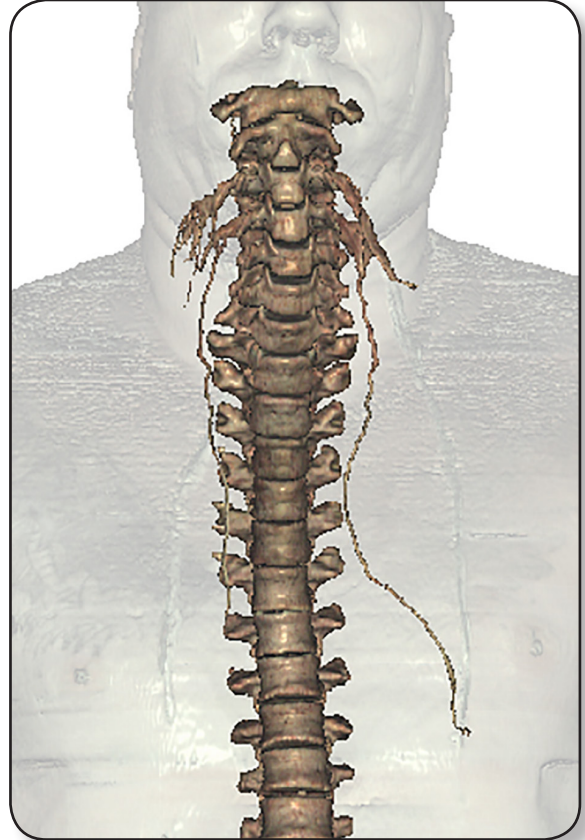
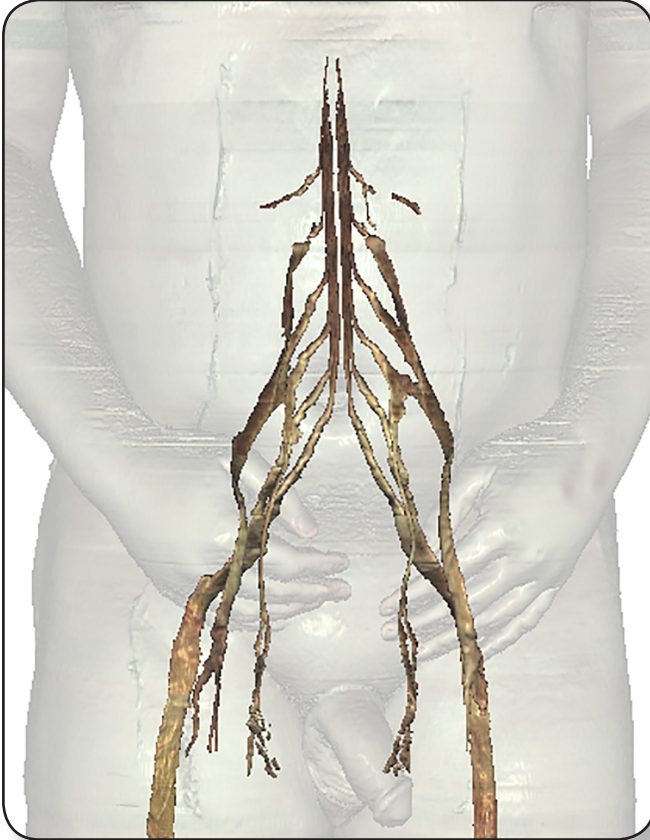---

---

# Spinal Cord & Spinal Nerves

Identify the following structures in the images below.  
(Some structures may be visible in more than one image.)

T1 nerve root • rami • phrenic nerve • femoral nerve  
obturator nerve • cervical plexus • lumbar plexus



Label the following using the descriptions provided in the Anatomy Pathways lesson.

- *conus medullaris*
- *cauda equina*

---

---

What is the *filum terminale*?

---

---