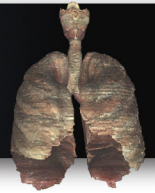

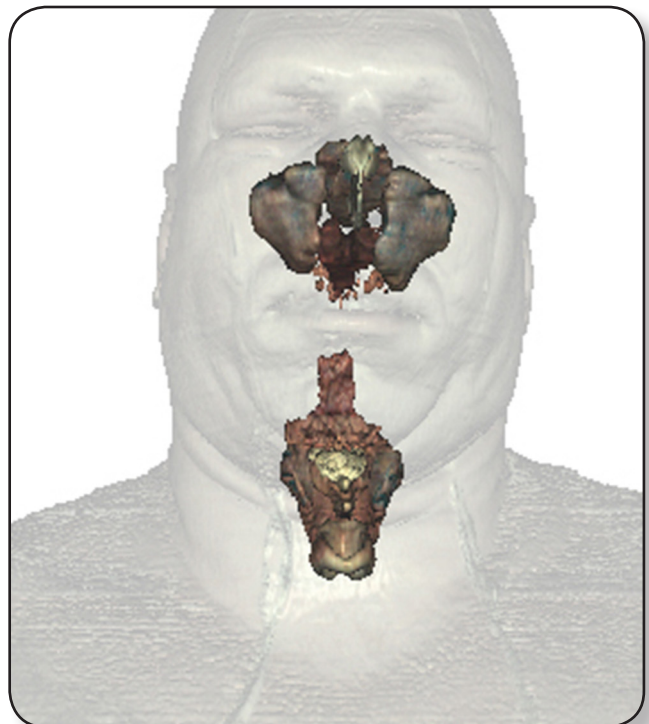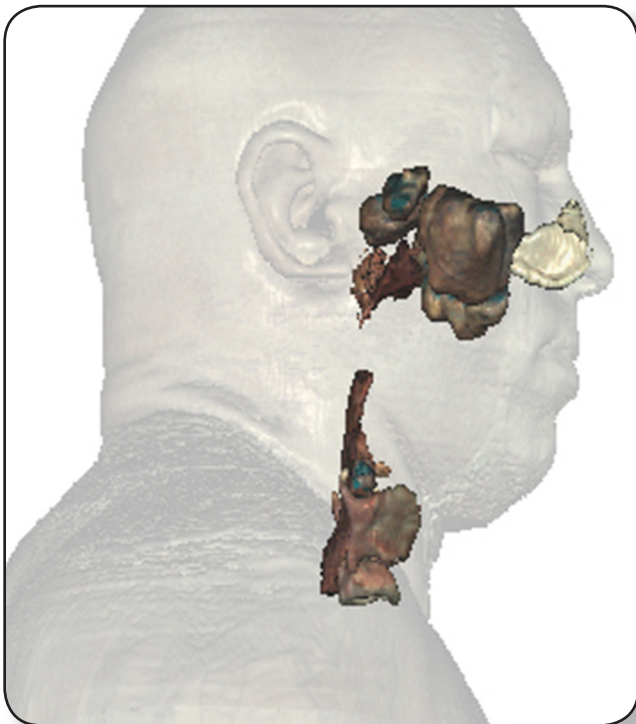# Anatomy Pathways™ for VH Dissector™

## Respiratory System



Identify the following structures in the images below.  
(Some structures may be visible in more than one image.)

septal nasal cartilage • sinuses (maxillary & sphenoidal) • nasopharynx  
oropharynx • laryngopharynx • pharyngeal tonsils • epiglottis • larynx  
thyroid cartilage • cricoid cartilage • vocal folds • vocal ligaments



What are *lung lobules*?

---

---

What is the *carina*?

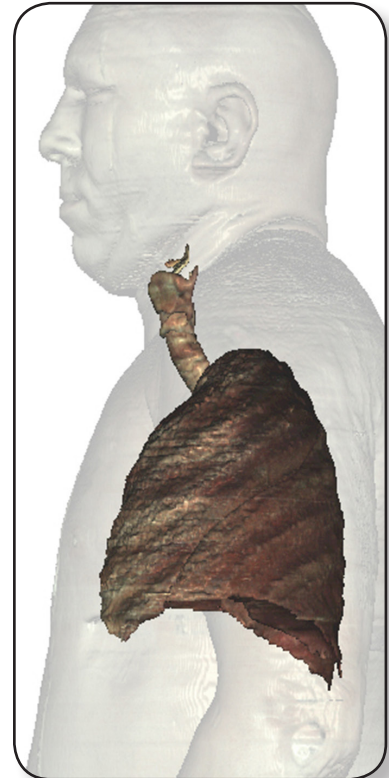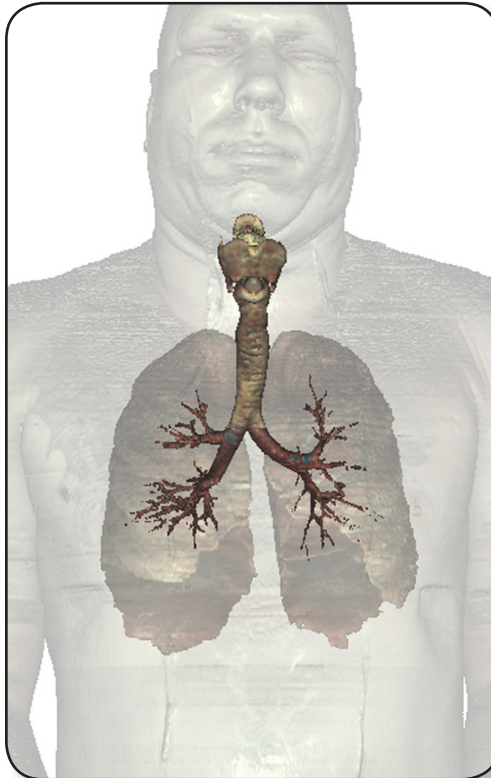
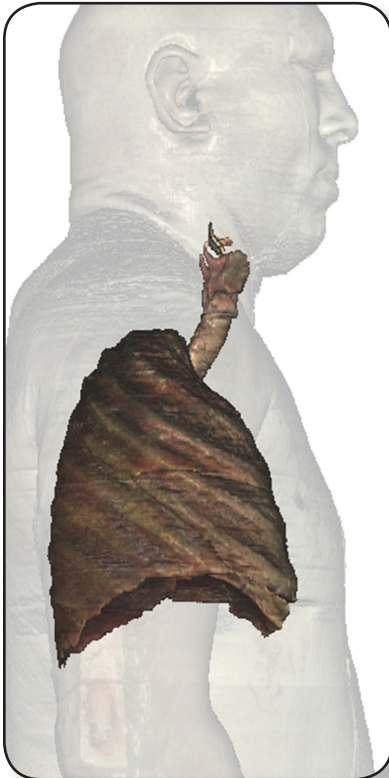---

---

# Respiratory System

Identify the following structures in the images below.  
(Some structures may be visible in more than one image.)

superior lobes • middle lobe • inferior lobes • horizontal fissure • oblique fissure  
lobules • bronchial tree (combination of bronchus and bronchi) • trachea • carina  
bronchi • main/primary bronchus • lobar bronchus • segmental bronchus • bronchioles



What are the *segmental bronchi*?

---

---

What are *bronchioles*?

---

---